"Why is my skin this color?"

Disorders of pigmentation

Scott A. Norton, MD, MPH
Chief of Dermatology

Children's National Medical Center

"Why is my skin this color?"

Disorders of pigmentation

No financial conflicts of interest.
Will discuss off-label uses.

Children's National Medical Center

"Why is my skin this color?"

- Terminology of Pigmentation
- Disorders of Hypopigmentation
- Disorders of Hyperpigmentation
- Treatment of Common Conditions
- When to Refer

Children's National Medical Center

4 components of normal skin pigmentation

Epidermal melanin (brown) -- most important pigment.
Oxygenated hemoglobin (red).
Deoxygenated hemoglobin (blue).
Carotenoids (yellow).

Causes of Macular (Flat) Hypo- & Hyperpigmentation

- Pityriasis versicolor
- Pigmentary demarcation lines
- Pityriasis alba
- Sarcoidosis
- Scleroderma
- Lupus erythematosis
- Physical agents
- Infections
- Mycosis fungoides
- Chemical agents
- Lichen sclerosis
- Vitiligo
- Nutritional disorders
- Endocrinopathies
- Idiopathic guttate hypomelanosis
- Confetti leukoderma
- Carney complex
- Peutz-Jeghers syndrome
- LEOPARD syndrome
- Neurofibromatosis type I
- Watson syndrome
- McCune-Albright syndrome
- Bloom syndrome
- Incontinentia pigmenti
- Canities
- Nevus anemicus
- Bier's spots
- Nevus o f Hori
- Lentigo
- Becker's nevus
- Ephelides
- Post-inflammatory hyperpigmentation
- Inherited patterned lentigenosis
- Acquired brachial cutaneous dyschromatosis
- Riehl melanosis
- Cutaneous amyloidosis
- Laugier-Huinziker syndrome
- Phytophotodermatitis
- Flagellate pigmentation
- Erythema ab igne
- Prurigo pigmentosum
- Fanconi anemia
- POEMS syndrome
- Cronkhite-Canada syndrome
- Progressive systemic sclerosis
- Nevus of Ota
- Nevus of Ito
- Mongolian spots

Disorders that are too light

Too light
↓
Is it Hypo- vs De- pigmented ?
↓
Is it Congenital or Acquired ?
↓
Is it Generalized or Focal ?

Hypopigmented


Depigmented or nonpigmented

Congenital generalized lack of pigment

Albinism (various types)

Albinism


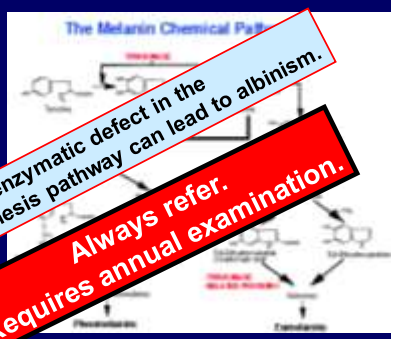

The point is – enzymatic defect in the melanin synthesis pathway can lead to albinism.

Always refer.
Requires annual examination.

http://albinism.med.umn

Congenital generalized hypopigmentation

Albinism variants
Various genetic disorders:
- Phenylketonuria (PKU),
- Chediak-Higashi,
- Griscelli,
- Hermansky-Pudlak
- etc.

Paternity issues

Always refer for diagnostic evaluation.

Congenital focal lack of pigment

Piebaldism
Tuberous sclerosis (ashleaf macules & confetti spots)
Nevus depigmentosus

Refer if syndromic.

Congenital focal lack of pigment

Piebaldism


White forelock, autosomal dominant, ventral > dorsal

Waardenburg's syndrome

Piebaldism
- white forelock
- other ventral midline sites

Sensorineural deafness

Pseudohypertelorism (dystopia canthorum)

Ashleaf macules & confetti spots of tuberous sclerosis

Tuberous sclerosis complex

Tumors of brain, heart, lungs, kidneys, eyes.
Seizures, mental retardation.
Autosomal dominant.

Angiofibromas (adenoma sebaceum)	Shagreen patch (lumbar or forehead)	Periungual fibromas

Nevus Depigmentosus

"Depigmentosus" is misnomer.
Usually hypopigmented, not nonpigmented.
Usually not ventral midline.
No white forelock or deafness. Nonsyndromic.

Nevus Depigmentosus

May be subtle and unnoticed at birth.
"Delayed birthmark"
No treatment. Fixed and stable – this is not vitiligo.

Congenital focal lack of pigment

Piebaldism
Tuberous sclerosis (ashleaf macules & confetti spots)
Nevus depigmentosus

Refer if syndromic.

Our approach to hypopigmenation

Too light

↓

Is it Hypo- vs De- pigmented ?

↓

Is it Congenital or Acquired ?

↓

Is it Generalized or Focal ?

Acquired focal depigmentation

Vitiligo

Jawaharlal Nehru, first Prime Minister of India, said that the three medical scourges of India are malaria, leprosy, and vitiligo.

Parsad D.
Quality of life in patients with vitiligo.
Health Qual Life Outcomes 2003;1:58-60

Normal

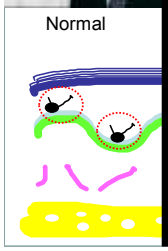

Acquired focal depigmentation

Vitiligo
Postinflammatory depigmentation
Lichen sclerosus (LS&A)

Chemical leukoderma
(Scleroderma)

Vitiligo

- Acquired disorder with depigmented macules, often symmetric.
- Eyes and mouth, elbows, knees, digits, genital area.

Vitiligo

- Well-circumscribed milky-white macules devoid of melanocytes.
- Risk for thyroiditis, alopecia areata, Addison's disease, diabetes, & pernicious anemia.
- Can be a psychosocial disaster!



Segmental Vitiligo


Treatment

Guidelines for the management of vitiligo. European Dermatology Forum Consensus.
British Journal of Dermatology 2013:168:5-19.

Treatment

Topical steroids:

- work best on sun-exposed surfaces; worst
- usual risks; no guidelin
- tria
- c

Simple vitiligo that doesn't respond, refer to general dermatologist.

Topical calcineurin inhibitors

- pimecrolimus (Elidel) or tacrolimus (Protopic) twice daily
- black box warning; insurance difficulties

Phototherapy (narrow band UVB) – probably most effective

Camouflage (Lydia O'Leary, DermaBlend, CoverMark)

Perianal and vulvar vitiligo

Often difficult to distinguish from lichen sclerosus (LS&A).

Refer.

Acquired focal depigmentation

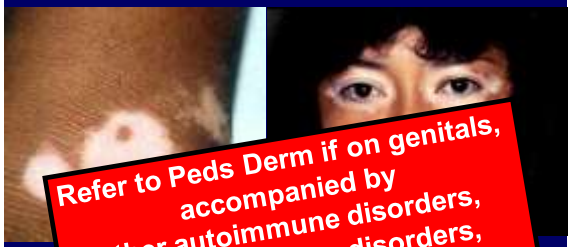

Refer to Peds Derm if on genitals, accompanied by other autoimmune disorders, connective tissue disorders, or eye pain & photophobia.

Acquired focal hypopigmentation

Tinea versicolor

Pityriasis alba

Post-inflammatory hypopigmentation

Don't refer – or send to a general dermatologist.

Tinea versicolor

- Ubiquitous fungus *Malassezia furfur* (*Pityrosporum* spp.)
- Clinically:
  - Versicolor: white, brown, red
  - Sharply demarcated hypo/hyperpigmented
  - Fine dusty scale
  - Trunk, neck, proximal arms

Diagnosis:

KOH prep. Don't get fungal culture.
Gentle scraping.

Treatment

New diagnosis:

Topical antifungals for two weeks.

- clotrimazole & miconazole are least expensive.
- terbinafine (Lamisil) & nystatin are ineffective.

Selenium sulfide (Selsun) or ketoconazole shampoo weekly

- get wet, lather up, wait 10 minutes, rinse
- ketoconazole 1% is OTC; 2% is prescription
- ciclopirox (Loprox) is too expensive
- goal to reduce (inevitable) re-"infection"

Treatment

Inform patient:

Pigmentation may take 2-4 months to restore.
Continue using body shampoo monthly.

If condition persists or relapses:

Oral agents: ketoconazole (dozens of regimens).
Griseofulvin & terbinafine (Lamisil) don't work.

Pityriasis alba

- Occasional feature of atopic dermatitis in children.
- Most common if medium pigmentation (Latinos, South Asians).
- Usually involves face.
- Post-inflammatory hypopigmentation.
- Resolves spontaneously.

Treatment

- Reassure.
- Explain that this is not vitiligo and it is not a fungus.
- Moisturize twice daily.
- No scrubbing of face.
- Hydrocortisone 1% or 2.5% daily for 2-3 weeks.
- Sunscreen to prevent accentuation of color difference

Post-inflammatory hypopigmentation

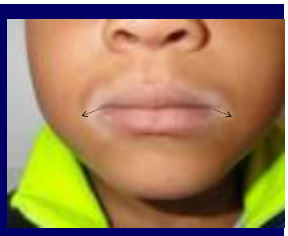

Lip licker's dermatitis

- Hypopigmentation extends beyond corners of mouth
- Treat with:
  - Education & reassurance.
  - Hydrocortisone 1% oint twice daily for 2 weeks then daily for 2 weeks then prn.
  - Barrier cream (zinc oxide) at bedtime.
  - Sunscreen.

Post-steroid hypopigmentation?

"That steroid cream bleached my kid."

- Not likely if cortisones are lower strength.
- Often a no-win situation.
- Consider calcineurin inhibitors, eg tacrolimus/Protopic.

Acquired focal hypopigmentation

Tinea versicolor

Pityriasis alba

Post-inflammatory hypopigmentation

Don't refer – or send to a general dermatologist.

Subtle hypopigmentation in the tropics

Pityriasis alba

Tinea versicolor

Leprosy, BL

The most common presentation of early leprosy is a hypopigmented patch or plaque with ↓ sensation.

End-stage leprosy

Madurosis
Lagophthalmos
Saddlenose deformity

Resorption of digits
Claw-hand deformity
Ape-hand deformity

Acquired focal hypopigmentation

Post-inflammatory hypopigmentation
Tinea versicolor
Pityriasis alba

Don't refer – or send to a general dermatologist.

Leprosy (Hansen's disease)

If anesthetic, refer to me.

Disorders that are "Too dark"

Too Dark
↓
Congenital or Acquired
↓
Generalized or Focal

Congenital generalized hyperpigmentation

Congenital melanosis "carbon baby"
Paternity issues

Whorls and swirls – refer ASAP.

Congenital focal hyperpigmentation

Mongolian spot & dermal melanosis
Congenital melanocytic nevi
Café-au-lait macules
Physiologic variants



Mongolian Spots

- Solitary or multiple.
- Few mm to many cm in diameter.
- Locations: sacrum, buttocks, back.
- Very common in Asians & African ethnicities.
- Many resolve over several years.
- May be mistaken for bruising (abuse).

Congenital dermal focal melanosis

Laser techniques for dermal melanosis are improving steadily.
(But CNMC does not have those particular lasers.)

Nevus of Ota

Melanocytes deep in the dermis.
May involve sclera & underlying mucosa.
Most common in Asian women.

Giant congenital melanocytic nevus

Refer – not urgently.

Acquired generalized hyperpigmentation

- Physiologic
- Suntanning
- Addisonian hyperpigmentation
- Genetic/metabolic disorders

- Diffuse melanosis (from melanoma)
- Drug-induced pigmentation

Acquired focal hyperpigmentation

Acanthosis nigricans
C.A.R.P.
Post-inflammatory hyperpigmentation
Becker's nevus

Medication-induced hyperpigmentation
Phytophotodermatitis
Melasma
Exogenous causes (tattoo etc.)

Acanthosis nigricans

- Velvety, grey-brown thickening.
- Posterior & lateral neckline, axillae, groin, inframammary.
- Obesity, metabolic syndrome

Obese teens with netlike discoloration of chest & back, resembling both acanthosis nigricans & tinea versicolor.

Confluent & Reticulated Papillomatosis of Gougerot & Carteaud

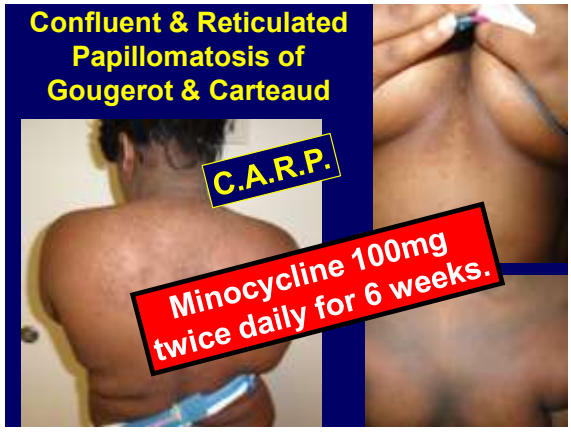

Post-inflammatory hyperpigmentation

Control underlying condition.
Time.

Post-inflammatory hyperpigmentation

Control acne.
Apply tretinoin nightly.
Apply hydroquinone 2% (Ambi) daily.
Time. Sunscreen.

Becker's Nevus

- Unilateral hyperpigmented and often hairy patch.
- Pectoral, scapular regions.
- Males> females.
- Onset in adolescence as a "delayed birthmark"

Normal Pigmentary Variants

Tuaregs.
The legendary "Blue People of the Desert"

"Why is my skin this color?"

Disorders of pigmentation

Scott A. Norton, MD, MPH
Chief of Dermatology

Children's National Medical Center