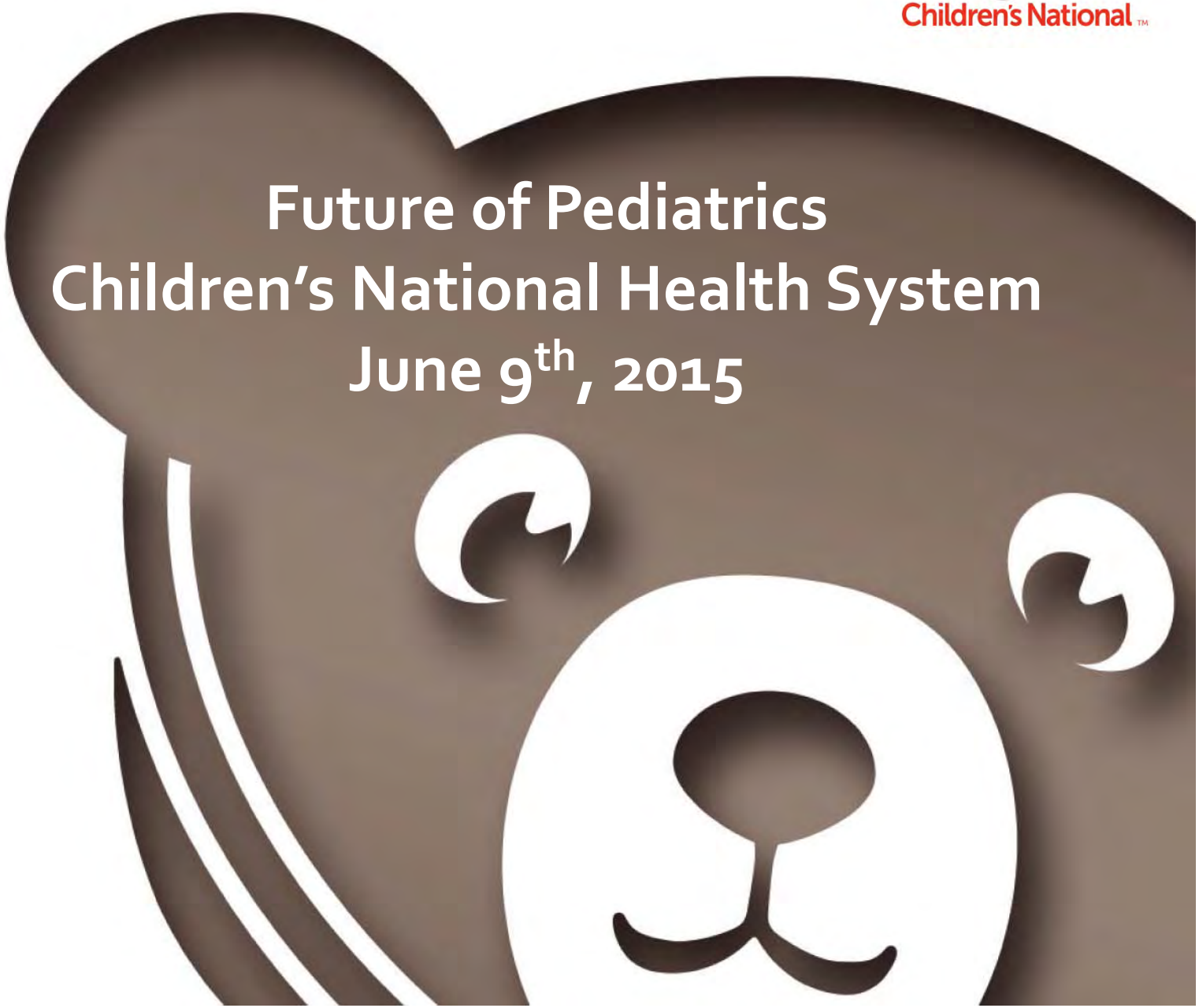

Children's National™

Future of Pediatrics
Children's National Health System
June 9th, 2015

Children's National™

Treatment of Infantile Hemangiomas

A. Yasmine Kirkorian MD
Clinical Assistant Professor of Dermatology

Disclosures

- I have no conflicts of interest or relevant financial relationships to disclose.
- I will be discussing off-label uses for certain medications.

Objectives

(1) Evaluate which infantile hemangiomas require treatment.

(2) Identify the role for propranolol in treating infantile hemangiomas.

(3) Identify the role for the use of topical timolol in treating infantile hemangiomas.

Benign vascular tumors	
Infantile hemangioma / Hemangioma of infancy	see details
Congenital hemangioma	
Rapidly involuting (RICH) *	
Non-involuting (NICH)	
Partially involuting (PICH)	
Tufted angioma * °	
Spindle-cell hemangioma	
Epithelioid hemangioma	
Pyogenic granuloma (aka lobular capillary hemangioma)	
Others	
Locally aggressive or borderline vascular tumors	
Kaposiform hemangioendothelioma * °	
Retiform hemangioendothelioma	
Papillary intralymphatic angioendothelioma (PILA), Dabska tumor	
Composite hemangioendothelioma	
Kaposi sarcoma	
Others	
Malignant vascular tumors	
Angiosarcoma	
Epithelioid hemangioendothelioma	
Others	

Who gets IH?

- 5-10% of all children
- Females
- Premature babies
- Multiple gestation babies
- Low birth weight babies
  - Most predictive

What are some potential complications of IH?

- Ulceration
- Disfigurement
- Cervicofacial ("beard") hemangiomas→ can be a marker for subglottic and upper airway IH
- Orbital IH→ visual impairment, amblyopia
- Proximity to Nose/Mouth→ airway obstruction
- Association with underlying syndromes
  - Typically with segmental IH

Why are outpatient pediatricians on the frontline for prevention of complications of infantile hemangiomas?

Key Observations

- 65% of children in this study had a precursor lesion present AT BIRTH.
- Most rapid growth between 5.5-7.5 weeks.
- Other studies have shown that infants with IH are referred to specialists between 3-5 months of age.
- This study supports referral by 4 weeks of age.

Key Point: Consult vascular anomaly experts early for proliferating vascular lesions.

cm
1
2
3

cm
NAME
AREA
1-800-631-6273
DATE

How do we treat IH?

A. Treatment is unnecessary, they will involute on their own in time
B. Propranolol
C. Hemangeol™
D. Prednisolone

CORRESPONDENCE

Propranolol for Severe Hemangiomas of Infancy

N Engl J Med 2008; 358:2649-2651 | June 12, 2008 | DOI: 10.1056/NEJMc0708819

Christine Léauté-Labrèze, M.D.
Eric Dumas de la Roque, M.D.
Thomas Hubiche, M.D.
Franck Boralevi, M.D., Ph.D.
Bordeaux Children's Hospital, 33 076 Bordeaux, France
christine.labreze@chu-bordeaux.fr

Jean-Benoît Thambo, M.D.
Haut-Lévêque Heart Hospital, 33 600 Pessac, France

Alain Taïeb, M.D.
Bordeaux Children's Hospital, 33 076 Bordeaux, France

Hemangeol™

- First FDA approved drug for treatment of IH. Approved March 2014.
- Active ingredient is propranolol.
- FDA-approved with BID dosing for infants > 5 weeks of adjusted age.

Propranolol Initiation

- Admission criteria and monitoring are institution dependent
- General agreement that neonates and babies with comorbid conditions should be admitted for inpatient initiation
- All others started as outpatient

What are potential adverse effects of propranolol?

- Bradycardia
- Hypotension
- Hypoglycemia
- Acral cyanosis
- Sleep disturbances
- Diarrhea/GI symptoms
- Cognitive concerns (memory formation)

At what age should I refer a patient for evaluation for propranolol?

- AS EARLY AS POSSIBLE
- Maximal proliferation has taken place by 12 weeks of age
- Size of IH should be considered within the context of age of patient→ a large IH in a 2-week-old is more likely to be problematic than in a similar lesion in an older child

Is there a treatment option for infantile hemangiomas that do not require systemic propranolol?

Topical Timolol Gel for small IH

Pediatrics. 2013 Jun;131(6):e1739-47. doi: 10.1542/peds.2012-3828. Epub 2013 May 6.

RCT of timolol maleate gel for superficial infantile hemangiomas in 5- to 24-week-olds.

Chan H[1], McKay C, Adams S, Wargon O.

Timolol Application

- Timolol Gel Forming Solution 0.5%
- Apply 1 drop BID to the infantile hemangioma
- Do not apply to mucosal surfaces or ulcerated infantile hemangiomas
- Pediatricians could consider prescribing timolol for small, superficial non-ulcerated infantile hemangiomas

Note: This is an off-label use of this medication.

Summary

- Infantile hemangiomas (IH) are the most common vascular tumor of infancy.
- The majority of the proliferation in an IH has taken place by 12 weeks of age→ early referral to a vascular anomalies specialist.
- Propranolol is now FDA approved for IH.
- Topical timolol gel is an alternate treatment option for small, focal superficial IH.

Questions?

A. Yasmine Kirkorian MD
akirkori@childrensnational.org